

A Survey on Skin Cancer Detection System

N.DurgaRao*, Dr. G.Sudhavani#

*Research Scholar, Department Of ECE, Acharya Nagarjuna University, Guntur, Andhra Pradesh, India.

#Professor, Department Of ECE, R.V.R & J.C College of Engineering, Guntur, Andhra Pradesh, India.

ABSTRACT

Skin cancers are the most common form of cancers found in humans. This is the most deadly form of cancer. Most of the skin cancers are curable at initial stages. So an early detection of skin cancer can save the patients. With the advancement of technology, early detection of skin cancer is possible. According to the literature, skin lesion structure is an important diagnostic parameter. In this paper, an introduction is given about different characteristics of the skin cancer and a brief review has been on types of skin cancer, skin cancer causes & symptoms. A survey has been given which carry out the analysis of skin cancer detection by different methods of the diagnosing methodology uses Image processing techniques. Finally, general method of skin cancer detection is presented with all possible image segmentation algorithms.

Keywords: basalcell carcinoma; melanoma; lesion; segmentation.

I. SKIN CANCER INTRODUCTION

Skin cancer is the most common of all human cancers, Cancer occurs when normal cells undergo a transformation and grow and multiply without normal controls. Here are the cancer basics:

- As the cells multiply, they form a mass called a tumor.
- Tumors are cancerous only if they are malignant. This means that they encroach on and invade neighboring tissues (especially lymph nodes) because of their uncontrolled growth.
- Tumors may also travel to remote organs via the blood stream. This process of invading and spreading to other organs is called metastasis.
- Tumors overwhelm surrounding tissues by invading their space and taking the oxygen and nutrients they need to survive and function.

There are three major types of skin cancers: basalcell carcinoma (BCC), squamous cell carcinoma (SCC), and melanoma. The first two skin cancers are grouped together as non-melanoma skin cancers. Other unusual types of skin cancer include Merkel cell tumors and dermatofibrosarcoma protuberans.

Here are the basics on skin cancers:

- The vast majority of skin cancers are basal cell carcinomas and squamous cells carcinomas. While malignant, these are unlikely to spread to other parts of the body. They may be locally disfiguring if not treated early.
- A small but significant number of skin cancers are malignant melanomas. Malignant melanoma is a highly aggressive cancer that tends to spread to other parts of the body. These cancers may be fatal if not treated early.

Like many cancers, skin cancers start as precancerous lesions. These precancerous lesions are changes in skin that are not cancer, but could become cancer over time. Medical professionals often refer to these changes as dysplasia. Some specific dysplastic changes that occur in skin are as follows:

- Actinic keratosis is an area of red or brown, scaly, rough skin, which can develop into squamous cell carcinoma. A nevus is a mole, and abnormal moles are called dysplastic nevi. These can potentially develop into melanoma over time.
- Moles are simply growths on the skin that rarely develop into cancer. Most people have 10 to 30 moles on their body that can be identified as flat or raised, smooth on the surface, round or oval in shape, pink, tan, brown or skin-colored, and no larger than a quarter-inch across. If a mole on your body looks different from the others, ask your health care provider to take a look at it.
- Dysplastic nevi, or abnormal moles, are not cancer, but they can become cancer. People sometimes have as many as 100 or more dysplastic nevi, which are usually irregular in shape, with notched or fading borders. Some may be flat or raised, and the surface may be smooth or rough ("pebbly"). They are often large, at a quarter-inch across or larger, and are typically of mixed color, including pink, red, tan, and brown.

II. SKIN CANCER CAUSES

Ultraviolet (UV) light exposure, most commonly from sunlight, is overwhelmingly the most frequent cause of skin cancer.

Other important causes of skin cancer include the following:

- Use of tanning booths.

- Immune suppression, or impairment of the immune system, which protects the body from germs or substances that cause an allergic reaction.
- Exposure to unusually high levels of radiation, such as from X-rays.
- Contact with certain chemicals, such as arsenic (miners, sheep shearers, and farmers) and hydrocarbons in tar, oils, and soot (which may cause squamous cell carcinoma).

The following people are at the greatest risk of skin cancer:

- People with fair skin, especially type that freckle, sunburn easily, or become painful in the sun.
- People with light (blond or red) hair and blue or green eyes.
- Those with certain genetic disorders that deplete skin pigment, such as albinism and xeroderma pigmentosum (a disease in which DNA repair mechanisms, especially in response to ultraviolet light, is impaired).
- People who have already been treated for skin cancer.
- People with numerous moles, unusual moles, or large moles that were present at birth.
- People with close family members who have developed skin cancer.
- People who had at least one severe sunburn early in life.
- People with burns unrelated to sunburn.
- People with indoor occupations and outdoor recreational habits.

Basal cell carcinomas and squamous cell carcinomas are more common in older people. Melanomas are more common in younger people, especially in people ages 25 to 29.

III. SKIN CANCER SYMPTOMS

Skin cancer symptoms depend on the type of skin cancer that has developed.

A basal cell carcinoma (BCC) usually looks like a raised, smooth, pearly bump on the sun-exposed skin of the head, neck, or shoulders. Other signs include:

- Small blood vessels may be visible within the tumor.
- A central depression with crusting and bleeding (ulceration) frequently develops.
- BCC often appears as a sore that does not heal.

A squamous cell carcinoma (SCC) is commonly a well-defined, red, scaling, thickened bump on sun-exposed skin. It may ulcerate and bleed, and left untreated, may develop into a large mass

The majority of malignant or cancerous melanomas are brown-to-black pigmented lesions. Other signs of a cancerous melanoma include:

- A change in size, shape, color, or elevation of a mole
- The appearance of a new mole during adulthood, or new pain, itching, ulceration, or bleeding of an existing mole

The following easy-to-remember guideline, "ABCDE," is useful for identifying malignant melanoma:

- **A**symmetry -- One side of the lesion does not look like the other.
- **B**order irregularity -- Margins may be notched or irregular.
- **C**olor -- Melanomas are often a mixture of black, tan, brown, blue, red, or white.
- **D**iameter -- Cancerous lesions can be larger than 6 mm across (about the size of a pencil eraser), although with early detection they will not reach this size.
- **E**volution -- has a mole changed over time?

IV. TYPES OF SKIN CANCERS

Skin cancer detection is divided into melanoma & non melanoma skin cancer. Types of non melanoma skin cancer.

Non melanoma skin cancer includes 2 main types:

- basal cell skin cancer (BCC)
- squamous cell skin cancer (SCC)

They're named after the types of skin cells where the cancer develops. It's possible for a non melanoma skin cancer to be a mixture of both these types. Non melanoma skin cancer is different from melanoma. Melanoma is the type of skin cancer that most often develops from a mole.

1) Basal-cell skin cancer

Basal-cell skin cancer (BCC) usually presents as a raised, smooth, pearly bump on the sun-exposed skin of the head, neck or shoulders. Sometimes small blood vessels can be seen within the tumor. Crusting and bleeding in the center of the tumor frequently develops. It is often mistaken for a sore that does not heal. This form of skin cancer is the least deadly and with proper treatment can be completely eliminated, often without scarring.

2) Squamous-cell skin cancer

Squamous-cell skin cancer (SCC) is commonly a red, scaling, thickened patch on sun-exposed skin. Some are firm hard nodules and dome shaped. Ulceration and bleeding may occur. When SCC is not treated, it may develop into a large mass. Squamous-cell is the second most common skin cancer. It is dangerous, but not nearly as dangerous as a melanoma.

3) Melanoma

Most melanoma consist of various colours from shades of brown to black. A small number of melanoma are pink, red or fleshy in colour; these

are called amelanotic melanoma and tend to be more aggressive. Warning signs of malignant melanoma include change in the size, shape, color or elevation of a mole. Other signs are the appearance of a new mole during adulthood or pain, itching, ulceration, redness around the site, or bleeding at the site. An often-used mnemonic is "ABCDE", where A is for "asymmetrical", B for "borders" (irregular: "Coast of Maine sign"), C for "color" (variegated), D for "diameter" (larger than 6 mm—the size of a pencil eraser) and E for "evolving."

II. LITERATURE SURVEY ON SKIN CANCER DETECTION

Jeffrey Glaister and David A. Clausi et al. [1] has compared his segmentation results on melanoma skin cancer images using joint statistical texture distinctiveness with those results obtained from other state-of-art algorithms. They have shown that their results have higher segmentation accuracy as compared to all other tested algorithms.

Ahmed A. Othman, Hamid R. Tizhoosh,[2] Member, IEEE, and Farzad Khalvati et al proposed the formation and evolution of fuzzy rules for user-oriented environments in which feedback is captured by design. The evolving fuzzy image segmentation (EFIS) can be used to adjust the parameters of existing segmentation methods, switch between their results, or fuse their results. Specifically, they proposed a single-parametric EFIS (SEFIS), apply its rule evolution to breast ultrasound images, and evaluated the results using three segmentation methods, namely, global thresholding, region growing, and statistical region merging. Their results show increased accuracy across all tests and for all methods.

Siti Noraini Sulaiman and Nor Ashidi Mat Isa et al. [3] proposed a new clustering algorithm called Adaptive Fuzzy-K- means clustering for image segmentation which could be applied on general images and/or specific images captured using different consumer electronic products. The algorithm employs the concepts of fuzziness and belongingness to provide a better and more adaptive clustering process as compared to several conventional clustering algorithms. Both qualitative and quantitative analyses favour the proposed AFKM algorithm in terms of providing a better segmentation performance for various types of images and various number of segmented regions. Based on the results obtained, the proposed algorithm gives better visual quality as compared to several other clustering methods.

Koushik Mondal et al. [4] proposed a fuzzy rule guided novel technique that is functional devoid of any external intervention during execution. Experimental results suggest that this approach is an

efficient one in comparison to different other techniques extensively addressed in literature. In order to justify the supremacy of performance of our proposed technique in respect of its competitors, we take recourse to effective metrics like Mean Squared Error (MSE), Mean Absolute Error (MAE), Peak Signal to Noise Ratio (PSNR).

Grigory Begelman and Michael Rudzsky et al. [5] demonstrated the usage of fuzzy classification engine in nuclei cell segmentation. The fuzzy rules were based on shape and colour features. Classification engine was set up with statistically estimated distribution parameters of image features and verified on a large microscope image data set. The fuzzy method exhibited better segmentation results than segmentation based on crisp rules.

Gandini S et al [6] A systematic revision of the literature was conducted in order to undertake a comprehensive meta- analysis of all published observational studies on melanoma. An extensive analysis of the inconsistencies and variability in the estimates was performed to provide some clues about its Epidemiology. Following a systematic literature search, relative risks (RRs) for sun exposure were extracted from 57 studies published before September 2002. Intermittent sun exposure and sunburn history were shown to play considerable roles as risk factors for melanoma, whereas a high occupational sun exposure seemed to be inversely associated to melanoma.

Nilkamal S. Ramteke , Shweta V.Jain et al [7] This paper first reviews the past and present technologies for skin cancer detections along with their relevant tools. Then it goes on discussing briefly about t features, advantages or drawbacks of each of them. Then we discuss the mathematics preliminary required to process the image of skin cancer lesion using our proposed scheme. This paper presents a new approach for Skin Cancer detection and analysis from g given photograph of patient's cancer affected area, which can be used to automate the diagnosis and theruptic treatment of skin cancer.

P. G. Cavalcanti and J. Scharcanski et al [8] This paper describes a new method for classifying pigmented skin lesions as benign or malignant. The skin lesion images are acquired with standard cameras, and our method can be used in telemedicine by non-specialists. Each acquired image undergoes a sequence of processing steps, namely: (1) preprocessing, where shading effects are attenuated; (2) segmentation, where a 3-channel image representation is generated and later used to distinguish between lesion and healthy skin areas; (3) feature extraction, where a quantitative representation for the lesion area is generated; and (4) lesion classification, producing an estimate if the lesion is benign or malignant (melanoma).

Mariam A.Sheha, Mai S.Mabrouk, Amr Sharawy, et al [9] This paper presents an automated method for melanoma diagnosis applied on a set of dermoscopy images. Features extracted are based on gray level Co-occurrence matrix (GLCM) and Using Multilayer perception classifier (MLP) to classify between Melanocytic Nevi and Malignant melanoma. MLP classifier was proposed with two different techniques in training and testing process: Automatic MLP and Traditional MLP. Results indicated that texture analysis is a useful method for discrimination of melanocytic skin tumors with high accuracy. The first technique, Automatic iteration counter is faster but the second one, Default iteration counter gives a better accuracy, which is 100 % for the training set and 92 % for the test set.

P. Haritha et al [10] Tree-structured wavelet transform and sub-band analysis of Curvelet Transform are used in this paper. Feature extraction and 8 sub-band stages on feature selection method, based on entropy and correlation, were applied to a train set of 15 images in this proposed method. The resultant feature subsets were then fed into neural network classifiers on 3 stages Normal, Disease Effected 30-50% and Disease Effected above 50% .Comparison measurement analysis on DWT /DCT Using NN Classifier is accurate than existing methods.

Shivangi Jain, Vandan jagtap, Nitin Pise et al [11] In this paper, we present a computer aided method for the detection of Melanoma Skin Cancer using Image Processing tools. The input to the system is the skin lesion image and then by applying novel image processing techniques, it analyses to conclude about the presence of skin cancer. The Lesion Image analysis tools checks for the various Melanoma parameters Like Asymmetry, Border, Colour, Diameter,(ABCD) etc. by texture, size and shape analysis for image segmentation and feature stages. The extracted feature parameters are used to classify the image as Normal skin and Melanoma cancer lesion.

Jisha Gopinath, Maya John et al [12] In this paper, Gabor filter is used for extracting features from the input medical image. Features of an image with skin lesion and an image having no skin lesion are extracted. Support vector machine and artificial neural network techniques are used for classification purpose.

Idris Nayaz Ahmed Chaya P et al [13] In this paper, Weiner Filter is implemented to remove noise and undesired structures from the images. In the Segmentation stage Distance Regularized Level Set (DRLS) method is implemented in order to acquire a contour by means of the gradient flow that minimizes an energy function with a distance regularization term and an external energy that drives the motion of the zero level set toward desired locations. Support

vector machine (SVM) classifier is employed for the classification task, utilizing feature vectors derived from gray level co-occurrence (GLCM) features.

Pablo G. Cavalcanti, Jacob Scharcanski, Leandro E. Di Persia and Diego H. Milone et al. [14] In this paper a new skin lesion segmentation method is proposed. This method uses Independent Component Analysis to locate skin lesions in the image, and this location information is further refined by a Level-set segmentation method. Our method was evaluated in 141 images and achieved an average segmentation error of 16.55%

V. GENERAL SKIN CANCER DETECTION SYSTEM

At first an image is acquired with a digital camera under consistent lighting. The proper interpretation of these dermoscopic images leads to increased clinical diagnostic accuracy.

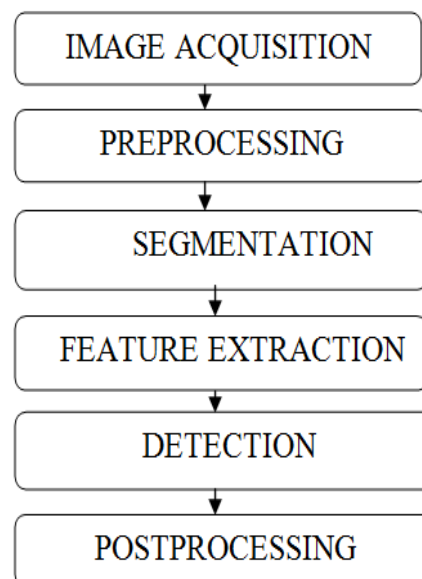


Fig: 1 Flowchart of skin cancer detection

Most Automated Skin Lesion Diagnosis methods adopt the standard computer-aided diagnosis (CAD) pipeline which is illustrated in Fig: 1 and it consists of five general stages. After the image is acquired, it contains many artifacts such as hair and oil bubbles which could bias downstream processes are identified. Next, the lesion is segmented from the surrounding healthy skin.

After segmentation, discriminative features are extracted from the lesion. Features which are usually extracted are border, color, entropy, compactness, radial variance of the mask, coarseness. Finally; by extracting these features the detection is done which finally shows the risk probability of the lesion which is present in the image. Mostly automatic skin cancer detection systems consist of following procedures:

(i) Image pre-processing – It is done to remove the noise and fine hair.

(ii) Post-processing – It is done to enhance the shape of image.

(iii) Segmentation - It is done to remove the healthy skin from the image and find the region of interest.

A. *Threshold Based Segmentation*

Histogram thresholding and slicing techniques are used to segment the image. They may be applied directly to an image, but can also be combined with pre- and post- processing techniques.

B. *Clustering Techniques*

Although clustering is sometimes used as a synonym for (agglomerative) segmentation techniques, we use it here to denote techniques that are primarily used in exploratory data analysis of high-dimensional measurement patterns. In this context, clustering methods attempt to group together patterns that are similar in some sense. This goal is very similar to what we are attempting to do when we segment an image, and indeed some clustering techniques can readily be applied for image segmentation.

C. *Discontinuity based Segmentation:*

Detection of lesion edges using active contours / radial search techniques / zero crossing of Laplacian of Gaussian (LoG). It covers: 1) Active contours 2) Radial search 3) LoG

D. *Region-based segmentation*

Splitting the image into smaller components then merging sub images which are adjacent and similar in some sense. It includes Statistical region merging, multi scale region growing, and morphological flooding [15-16]. It is based on the following techniques: 1) Split and merge 2) Statistical Region Merging 3) Multi-scale 4) Morphological flooding

E. *Soft computing*

Soft computing techniques do the categorization of pixels using soft computing techniques [16-18]. It includes: 1) Fuzzy logic 2) Neural Network 3) Optimization algorithms

(iv) Feature Extraction -As per ABCD rule the features which we need to extract include Asymmetry Index, Border, Color Index ,Diameter.

(v) Post Processing-The result of the segmentation procedure is either a label image or a binary edge map. In order to obtain the lesion border, the segmentation output should be postprocessed. The precise sequence of postprocessing operations depends on the particular choice of the segmentation method.

VI. CONCLUSION

According to the literature, pigment structure is an important diagnostic parameter for skin cancer .Different literature work address the problem of how to determine the absence or presence of pigment lesion in a given dermoscopic image. Some define it as a typical pigment lesion is which is light-to-dark brown in color with small, uniformly spaced network holes and thin network lines distributed more or less regularly throughout the lesion and usually thinning out at the periphery. Most of the methods are robust, reliable, computer-aided diagnostic tool for analyzing the texture in lesions of the skin to detect pigment networks in the presence of other structures such as dots. Different methods used different methods for extraction of feature set as well as final classification in terms of present or absent of the skin cancer lesion in the image. Different image segmentation methods give an idea for implementation of generalized skin cancer detection technique.

REFERENCES

- [1] Jeffrey Glaister, Alexander Wong, David A. Clausi, "Segmentation Of Skin Lesions From Digital Images Using Joint Statistical Texture Distinctiveness" Ieee Transactions On Biomedical Engineering, Vol. 61, No. 4, April 2014 Page(1220-1230)
- [2] A Othman, HR Tizhoosh, F Khalvati "Evolving Fuzzy Image Segmentation", Fuzzy Systems, IEEE Transactions on, Volume 22 ,issue-1, 2014
- [3] Siti Noraini Sulaiman , Nor Ashidi Mat-Isa, Nor Hayati Othman , Fadzil Ahmad, "Improvement of Features Extraction Process and Classification of Cervical Cancer for the NeuralPap System", Procedia Computer Science 01/2015; 60:750-759.
- [4] VprBP binds full-length RAG1 and is required for B-cell development and V(D) J recombination fidelity ,The EMBO Journal (Impact Factor: 10.43). 12/2011; 31(4):945-58
- [5] Roman Goldenberg , Dov Eilat, Grigory Begelman, Eugene Walach, Eyal Ben-Ishai, Nathan Peled International Journal of Computer Assisted Radiology and Surgery 11/2012; 7(6):819-27. DOI:10.1007/s11548-012-0684-7 • 1.71 Impact
- [6] Gandini S, Meta analysis of risk factors for cutaneous melanoma: II. Sun exposure. European Journal of Cancer; 41: 1, 45-60. (2005)
- [7] Nilkamal S. Ramteke, Shweta V. Jain, "Analysis of Skin Cancer Using Fuzzy and Wavelet Technique – Review & Proposed New Algorithm". International Journal of

- Engineering Trends and Technology (IJETT). V4(6):2555-2566 Jun 2013.
- [8] P. G. Cavalcanti and J. Scharcanski, "Automated prescreening of pigmented skin lesions using standard cameras", *Comput.Med. Imag. Graph.*, vol. 35, no. 6, pp. 481–491, Sep. 2011
- [9] Mariam A.Sheha ,Mai S.Mabrouk ,Amr Sharawy " Automatic Detection Of Melanoma Skin Cancer Using Texture Analysis" *International Journal Of Computer Applications* (0975 – 8887), Volume 42–No.20, March 2012 ,Page(22-26).
- [10] P. Haritha "Classification Of Non-Melanoma Lesions Using Wavelet And Curvelet Based Texture Analysis" *Ijsetr* , Issn 2319-8885 Vol.04,Issue.52, December-2015, Pages:11100-11105
- [11] Shivangi Jain, Vandan jagtap, Nitin Pise, "Computer aided Melanoma skin cancer detection using Image Processing", (ICCC-2015), *Procedia Computer Science* 48 (2015) 735 – 740.
- [12] Jisha Gopinath, Maya John , "Feature Extraction by Gabor Filter and Classification of Skin Lesion using Support Vector Machine", *IJIRCCE*, Vol. 3, Issue 10, October 2015
- [13] Idris Nayaz Ahmed, Chaya P , "Segmentation and Classification of Skin Cancer Images" , *IJARCSSE*, Volume 4, Issue 5, May 2014
- [14] Pablo G. Cavalcanti, Jacob Scharcanski, Leandro E. Di Persia and Diego H. Milone , " An ICA-Based Method for the Segmentation of Pigmented Skin Lesions in Macroscopic Images", 33rd Annual International Conference of the IEEE EMBS ,August 30 - September 3, 2011
- [15] V. De Vita, G. L. Di Leo, G. Fabbrocini, C. Liguori, A. Paolillo, and P. Sommella, "Statistical techniques applied to the automatic diagnosis of dermoscopic images," *ACTA IMEKO*, vol.1, no. 1, pp. 7–18, 2012.
- [16] K. Ramlakhan and Y. Shang, "A mobile automated skin lesion classification system," in *Proceedings of the 23rd IEEE International Conference on Tools with Artificial Intelligence (ICTAI '11)*, pp. 138–141, November 2011.
- [17] D. Ruiz, V. Berenguer, A. Soriano, and B. S´anchez, " A decision support system for the diagnosis of melanoma: a comparative approach," *Expert Systems with Applications*, vol. 38, no. 12, pp. 15217–15223, 2011.
- [18] R. Parikh, H. Shah, "A Survey on Computer Vision Based Diagnosis for Skin Lesion Detection", *International Journal of Engineering Science and Innovative*
- Technology (IJESIT) Volume 2, Issue 2, March 2013.